



PATIENT

Princess Becerra

SPECIES

Canine

BREED

Pitbull

SEX

F

AGE

8 years

WEIGHT

68.6 lbs

INTERPRETED BY

Maggie Machen Lamy,
DVM, DACVIM
(Cardiology)

IMAGING PERFORMED BY

PRESENTING CLINICAL SIGNS

History: Recheck. No further history provided
Current medications: Diltiazem 90mg PO q8h; Pimobendan 10mg PO q12h.
Pertinent echo findings (MML 2/22): CVD mod; FS 24%
Pertinent holter results (MML 10/2021): short PR with wide QRS; occ APCs, 2 paroxysms of SVT; otherwise NSR

HOLTER MONITOR FINDINGS AND RHYTHM ASSESSMENT

Time analyzed	22:20h
Mean heart rate	63bpm
Maximum heart rate	211bpm
Minimum heart rate	30bpm
VPCs	4 singles
APCs	90; 21 singles, 2 runs

Interpretation: Underlying normal sinus rhythm with apparently appropriate rate variation persists. Unchanged QRS morphology/PR interval. Rare VPCs noted. Occasional APCs with 2 paroxysms of SVT; HR 240bpm.

Rhythm diagnosis: Sinus rhythm with paroxysmal SVT; apparently well controlled. Occasional ventricular ectopy. Bundle branch block.

RECOMMENDATIONS

The holter results are similar to previous, with brief rare SVT. The 2 runs occur at 2am and 12pm, making it difficult to know if stress/activity is correlated. No significant change from the prior recording.

No changes to the medications are indicated at this time. Should the patient experience any related clinical signs in the future (acute lethargy, syncope), consider change to Sotalol at that time. Unfortunately even with apparently good control the patient will always be at risk for break through arrhythmias, syncope and/or sudden death.

Mild activity restriction is advised lifelong.

Reassess a holter every 6-12months, or should symptoms develop in the future.

HOSPITAL NAME

Englewood
Veterinary Center

REFERRING VET

Dr. Ezik

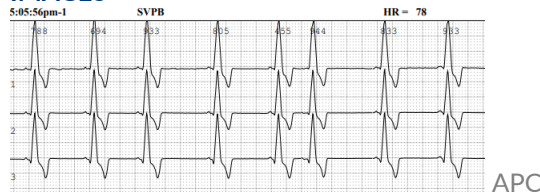
INVOICE

24010

DATE

5/3/22

IMAGES





PATIENT

Princess Becerra

SPECIES

Canine

BREED

Pitbull

SEX

F

AGE

8 years

WEIGHT

68.6 lbs

INTERPRETED BY

Maggie Machen Lamy,
DVM, DACVIM
(Cardiology)

IMAGING PERFORMED BY

HOSPITAL NAME

Englewood
Veterinary Center

REFERRING VET

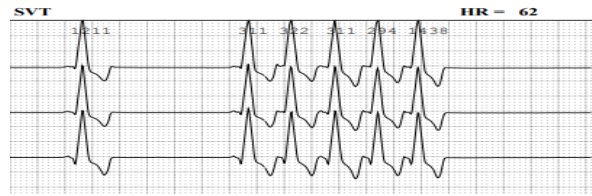Dr. Ezik

INVOICE

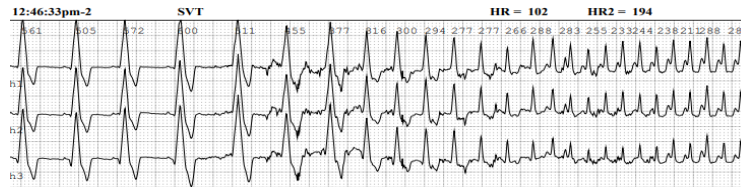
24010

DATE

5/3/22



Brief SVT presumably during sleep



SVT

The information and recommendations provided are based on the images presented by the referring veterinarian. No evaluation can be communicated regarding pathology that was not visible in the image/video clips provided.

Thank you for this referral. If the clinical or image interpretation does not parallel your findings or if I can be of any further assistance please contact me.

Maggie Machen Lamy, DVM
Diplomate of the American College of Veterinary Internal Medicine (Cardiology)
info@sonopath.com